KJA
Korean Journal of Anesthesiology

Ultrasound-guided percutaneous intercostal nerve cryoneurolysis for analgesia following traumatic rib fracture
-a case series-

Case Report

Korean J Anesthesiol 2020;73(5):455-459
https://doi.org/10.4097/kja.19395
pISSN 2005-6419 • eISSN 2005-7563

Received: September 27, 2019
Accepted: November 4, 2019

Corresponding author:
John J. Finneran IV, MD
Departments of Anesthesiology, University of California, 200 West Arbor Drive MC 8770
San Diego, CA 92103, USA
Tel: +1-408-307-3004
Fax: +1-619-543-6162
Email: jfinneran@ucsd.edu
ORCID: https://orcid.org/0000-0002-0955-155X

© The Korean Society of Anesthesiologists, 2020
This is an open-access article distributed under the terms of the Creative Commons Attribution license (http://creativecommons.org/licenses/by/4.0/), which permits unrestricted use, distribution, and reproduction in any medium, provided the original work is properly cited.

John J. Finneran IV[1], Rodney A. Gabriel[1], Matthew W. Swisher[1], Allison E. Berndtson[2], Laura N. Godat[2], Todd W. Costantini[2], Brian M. Ilfeld[1]

Departments of [1]Anesthesiology, [2]Surgery, University of California, San Diego, La Jolla, CA, USA

Background: Rib fractures are a common injury in trauma patients and account for significant morbidity and mortality within this population. Local anesthetic-based nerve blocks have been demonstrated to provide significant pain relief and reduce complications. However, the analgesia provided by these blocks is limited to hours for single injection blocks or days for continuous infusions, while the duration of this pain often lasts weeks.
Case: This case series describes five patients with rib fractures whose pain was successfully treated with cryoneurolysis.
Conclusions: Ultrasound-guided percutaneous cryoneurolysis is a modality that has the potential to provide analgesia matching the duration of pain following rib fractures.

Keywords: Analgesia; Cryoablation; Nerve block; Rib fracture; Trauma; Ultrasound.

Rib fractures occur in approximately 10% of trauma patients and represent a significant source of morbidity [1]. Pain from rib fractures is associated with decreased ability to cough and deeply inspire, predisposing patients to atelectasis and pulmonary complications. Both thoracic epidurals and paravertebral blocks have been associated with decreased pain, pulmonary complications, and mortality in patients with rib fractures [2]. Furthermore, intercostal nerve blocks with local anesthetic have been shown to improve pain control, peak expiratory flow rates, and arterial oxygen saturation on room air [3]. Unfortunately, single-injection intercostal blocks with bupivacaine resolve in as little as 6 hours [4], likely due to the high vascularity and consequent uptake of local anesthetic. Continuous blocks (epidural or paravertebral) may extend the duration of analgesia, yet these are still limited to a matter of days. Catheter placement also increases the risk of infection and may prevent initiation of anticoagulation therapy.

Recently, a new analgesic modality has been used by anesthesiologists for management of acute pain: ultrasound-guided percutaneous cryoneurolysis [5]. This technique, which has previously been used primarily to treat chronic pain, uses extremely cold temperatures (~ −70° Celsius) to reversibly ablate peripheral nerves. The neurons undergo Wallerian degeneration distally from the site of ablation, and the induced block lasts as long as the time for regeneration of the axons. In the case of intercostal cryoneurolysis for rib fractures, this has the potential to provide weeks of analgesia. We present five patients

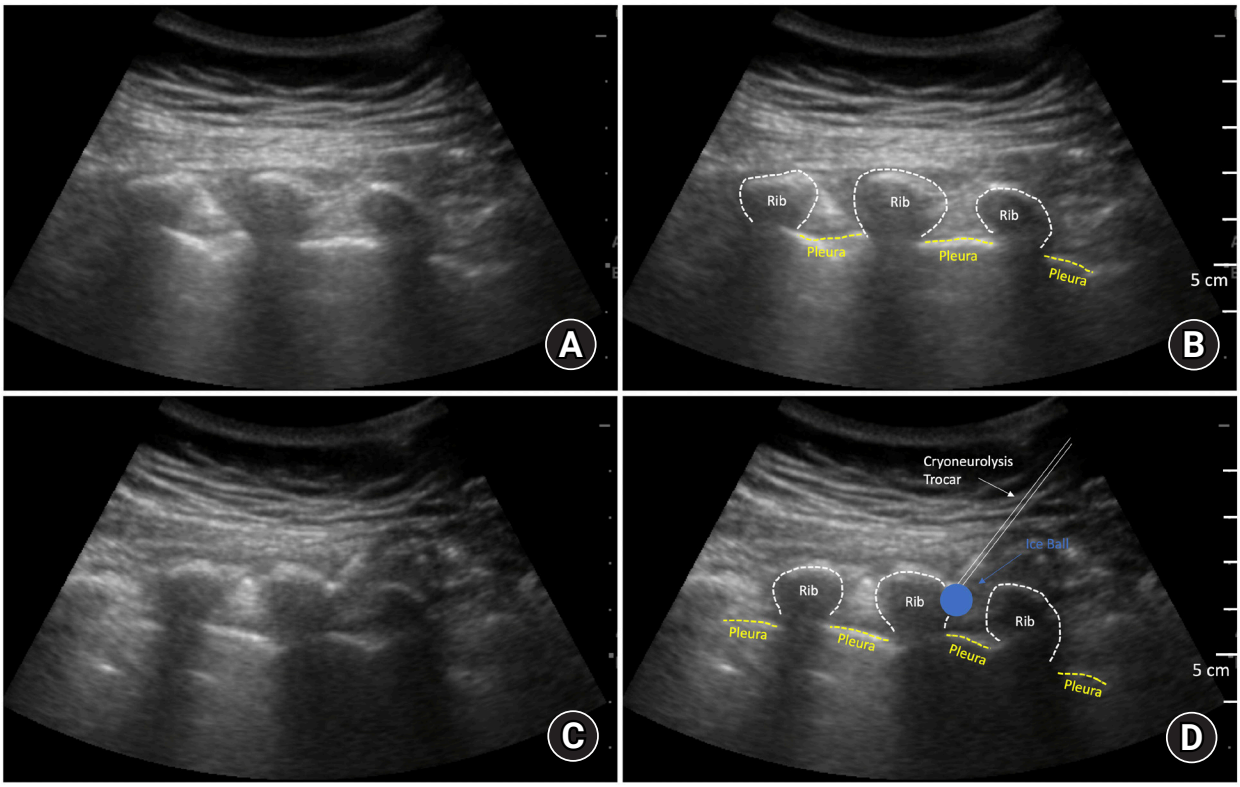

Fig. 1. Ultrasound-guided percutaneous cryoneurolysis. (A) Parasagittal ultrasound view of T5–T8 intercostal nerves prior to cryoneurolysis, (B) Labeled anatomy of image A, (C) Parasagittal ultrasound view of cryoneurolysis of T7 intercostal nerve, (D) Labeled anatomy of image C. Cyan circle indicates area of ice ball created from cryoneurolysis, white line: trajectory of cryoneurolysis probe.

who underwent ultrasound guided percutaneous intercostal cryoneurolysis for rib fracture pain (three who received only cryoneurolysis therapy and two who received both cryoneurolysis and a local anesthetic block) with sustained analgesia following the procedure.

Case Reports

The University's Institutional Review Board (University of California San Diego) waives review requirements for short case series. Written informed consent for the cryoneurolysis procedure and publication of relevant, non-identifiable history and imaging in the form of a case report was obtained from all patients.

Case 1

An 80-year-old female with a history of type-II diabetes mellitus, hypertension, congestive heart failure, and chronic kidney disease presented after falling out of bed with left-sided 4th through 8th rib fractures. Despite aggressive treatment in the intensive care unit, the patient's pulmonary status deteriorated over the following 24 hours and she was intubated for respiratory failure. During trials of spontaneous breathing the following morning, the patient was unable to take adequate tidal volumes and rapidly desaturated. Single-injection local anesthetic-based intercostal nerve blocks and cryoneurolysis to each intercostal nerve associated with a fractured rib (left 4th – 8th) was planned in the hope that the analgesia from the cryoneurolysis would not only facilitate extubation, but also provide long lasting relief.

The patient was positioned prone in a ProneView cushion (Mizuho OSI Inc., USA) and the 4th–8th ribs were identified using a curvilinear ultrasound transducer (SonoSite M-Turbo®, USA). At each level, an intercostal nerve block was performed just distal to the costotransverse joint, using an in-plane ultrasound guided technique and 20-gauge Tuohy needle to deliver 4 ml 0.5% bupivacaine with 2.5 μg/ml of epinephrine [3]. After each local anesthetic block, the probe of a hand-held cryoneurolysis device (Iovera®, Myoscience, USA) was advanced under ultrasound guidance toward the intercostal nerve, and two 2-minute freeze-thaw cycles were applied to each intercostal nerve (Fig. 1). Over the following 12 hours, the patient's opioid analgesic requirement decreased precipitously, and she was successfully extubated. The patient remained in the intensive care unit for two additional days, but she did not require re-intubation and her pain was well

https://doi.org/10.4097/kja.19395

controlled without opioid analgesics.

Nine days following the cryoneurolysis procedure, the patient's rib fracture pain returned; however, the pain at this time was manageable with oral acetaminophen and extended release lidocaine patches and was not associated with pulmonary compromise.

Case 2

A 64-year-old woman with a history of hypertension and osteoporosis presented with right 4th–8th rib fractures after a fall from standing height. At rest, the patient rated her pain as 3/10; however, this increased to 10/10 with coughing or incentive spirometer (IS) use. The patient was unable to cough due to the pain and had significant difficulty getting out of bed to walk with physical therapy. The patient underwent intercostal cryoneurolysis of the right 4th–8th intercostal nerves (without a local anesthetic nerve block). Two 2-minute freeze-thaw cycles applied to each intercostal nerve using a console cryoneurolysis device (PainBlocker™, Epimed International, USA). Within 1 hour after cryoneurolysis, the patient's pain at rest had decreased to 0/10, her pain with coughing and IS use was rated 3/10, and her IS values increased from 500 ml to 1,500 ml. The patient reported similar pain scores and IS values for the subsequent two days.

Twenty-one days following the cryoneurolysis procedure the patient noticed an increase in her pain, with her resting pain scores increasing to 3/10 and pain scores during incentive spirometry increasing to 5/10. The pain at this time was easily controllable with oral analgesics.

Case 3

A 73-year-old man with a medical history significant for atrial fibrillation, heart failure, type-II diabetes mellitus, and rectal and thyroid cancer presented with right 3rd–6th rib fractures after a motor vehicle accident. The patient reported a pain score of 6/10 at rest, which increased to 8/10 with IS use and coughing. Cryoneurolysis of the right 3rd–6th intercostal nerves was performed as described above using a console cryoneurolysis device (PainBlocker™, Epimed International, USA). After which, the patient reported pain scores of 2/10 at rest and 4/10 with IS use and coughing. His IS values increased from 1,000 ml to 1,750 ml. The patient was discharged on the second day following the procedure and at that time continued to report similar pain scores. He did not report noticing a significant increase in his pain at any point during the subsequent month.

Case 4

A 54-year-old previously healthy man presented to the emergency department approximately three weeks after sustaining left 3rd–11th rib fractures during a fall while rock climbing. At the time of the accident, he underwent a video assisted thoracoscopic surgery with rib plating of the 4th–8th ribs at an outside hospital. The patient continued to have significant pain, 8/10 at rest, 10/10 with IS use or coughing. Intercostal cryoneurolysis was performed as described above using a console cryoneurolysis device (PainBlocker™, Epimed International, USA). Immediately following the procedure, the patient rated his pain at rest as 0/10, increasing to 6/10 with coughing or IS use. The following day, his resting pain score was rated 3/10, increasing to 7/10 with IS use. The patient's pain was manageable with non-opioid analgesics and he did not report a significant increase in his pain over the following month.

Case 5

A 51-year-old previously healthy man presented with fractures of the right 1st–8th ribs and left 1st–6th ribs after an all-terrain vehicle accident. The patient received bilateral T5 paravertebral catheters, which provided excellent analgesia. However, the patient was unable to be weaned from the paravertebral infusions due to extreme pain when the infusions were discontinued. Therefore, intercostal cryoneurolysis was performed, first to the left 2nd–6th intercostal nerves, using a console cryoneurolysis device (PainBlocker™, Epimed International, USA). This resulted in a reduction in the patient's left sided chest pain after discontinuing the left paravertebral infusion from a score of 10/10 at rest to 0/10. On the following day, right sided intercostal cryoneurolysis was performed to the right 4th–7th intercostal nerves. This resulted in the resting pain level decreasing from 8/10 to 1/10 and allowing the patient to cough and use his IS. The following day resting pain scores were 2/10 bilaterally and 7/10 when coughing or using the IS. Fifteen days after the first cryoneurolysis procedure, the patient did note a minor increase in pain. However, his pain did remain controllable with oral analgesics.

Long Term Follow-up

At 3-month follow-up, no adverse events or symptoms of neuropathic pain were reported by any patient.

Discussion

Given the limits on the duration of local anesthetic-based nerve

blocks and the prolonged pain that is associated with rib fractures, ultrasound-guided percutaneous cryoneurolysis of the intercostal nerves may be an excellent adjuvant or substitute for local anesthetic-based nerve blocks. In this case series, cryoneurolysis was able to facilitate extubation and improve incentive spirometry use (decreasing the likelihood of intubation) in patients. Decreased length of intubation or avoidance of intubation is associated with significantly reduced incidence of pulmonary infection [1,6].

The physiological mechanism for cryoneurolysis analgesia is well established and its use relatively common in treating chronic pain. Nerves exposed to extremely cold temperatures exhibit an extended but reversible block. After cryoneurolysis, the neuronal axons undergo Wallerian degeneration distal to the site of treatment [7]. If the entire nerve is adequately treated, the degeneration is consistent across the nerve bundle. Regrowth of axons into the perineurium, which remains intact after cryoneurolysis, eventually restores sensation and the block functionally resolves [8].

As with any therapeutic modality, caution must be used when implementing a new tech^h^nique. Intercostal local anesthetic-based nerve blocks have an incidence of pneumothorax that may be over 1% [9], and it is reasonable to assume intercostal cryoneurolysis holds a similar risk (although with a more-blunt probe—compared with a sharper needle—the risk may be decreased). Large randomized trials will be required to fully evaluate the risk-benefit ratio of intercostal cryoneurolysis for traumatic rib fractures prior to widespread adoption of the technique.

Funding Statement

Myoscience (Fremont, California) and Epimed International (Farmers Branch, TX) provided the cryoneurolysis devices and probes used for these cases.

Conflicts of Interest

John J. Finneran (Dr. Finneran's institution has received funding and/or product for his research from Myoscience, Epimed, Ferrosan Medical, and SPR Therapeutics)
Rodney A. Gabriel (Dr. Gabriel's institution has received funding and/or product for his research from Myoscience, Epimed, Infutronics, Ferrosan Medical, and SPR Therapeutics)
Matthew W. Swisher (Dr. Swisher's institution has received funding and/or product for his research from Myoscience, Epimed, Ferrosan Medical, and SPR Therapeutics)
Allison E. Berndtson (Dr. Berndtson's institution has received product used in this report from Myoscience and Epimed)
Laura N. Godat (Dr. Godat's institution has received product used in this report from Myoscience and Epimed)
Todd W. Costantini (Dr. Costantini's institution has received product used in this report from Myoscience and Epimed)
Brian M. Ilfeld (Dr. Ilfeld's institution has received funding and/or product for his research from Myoscience, Epimed, Infutronics, Ferrosan Medical, Heron Pharmaceuticals, and SPR Therapeutics)

Author Contributions

John Finneran (Conceptualization; Data curation; Methodology; Writing – original draft; Writing – review & editing)
Rodney Gabriel (Conceptualization; Methodology; Writing – review & editing)
Matthew Swisher (Conceptualization; Methodology; Writing – review & editing)
Allison Berndtson (Conceptualization; Methodology; Writing – review & editing)
Laura Godat (Conceptualization; Methodology; Writing – review & editing)
Todd Costantini (Conceptualization; Methodology; Writing – review & editing)
Brian Ilfeld (Conceptualization; Funding; Methodology; Writing – review & editing)

ORCID

John J. Finneran, https://orcid.org/0000-0002-0955-155X
Rodney A. Gabriel, https://orcid.org/0000-0003-4443-0021
Matthew W. Swisher, https://orcid.org/0000-0003-2196-6288
Allison E. Berndtson, https://orcid.org/0000-0002-7299-453X
Laura N. Godat, https://orcid.org/0000-0003-4088-2418
Todd W. Costantini, https://orcid.org/0000-0002-0215-5327
Brian M. Ilfeld, https://orcid.org/0000-0002-6144-3273

References

1. Ziegler DW, Agarwal NN. The morbidity and mortality of rib fractures. J Trauma 1994; 37: 975-9.
2. Malekpour M, Hashmi A, Dove J, Torres D, Wild J. Analgesic choice in management of rib fractures: paravertebral block or epidural analgesia. Anesth Analg 2017; 124: 1906-11.
3. Osinowo OA, Zahrani M, Softah A. Effect of intercostal nerve block with 0.5% bupivacaine on peak expiratory flow rate and arterial oxygen saturation in rib fractures. J Trauma 2004; 56: 345-7.
4. Pedersen VM, Schulze S, Høier-Madsen K, Halkier E. Air-flow

https://doi.org/10.4097/kja.19395

meter assessment of the effect of intercostal nerve block on respiratory function in rib fractures. Acta Chir Scand 1983; 149: 119-20.
5. Gabriel RA, Finneran JJ, Asokan D, Trescot AM, Sandhu NS, Ilfeld BM. Ultrasound-guided percutaneous cryoneurolysis for acute pain management: a case report. A A Case Per 2017; 9: 129-32.
6. Bollinger CT, Van Eeden SF. Treatment of multiple rib fractures, randomized controlled trial comparing ventilation with non-ventilation management. Chest 1990; 97: 943-8.
7. Barnard D. The effects of extreme cold on sensory nerves. Ann R Surg Engl 1980; 62: 180-7.
8. Trescot AM. Cryoanalgesia in interventional pain management. Pain Physician 2003; 6: 345-60.
9. Shanti C, Carlin A, Tyburski J. Incidence of pneumothorax from intercostal nerve block for analgesia in rib fractures. J Trauma 2001; 51: 536-9.